

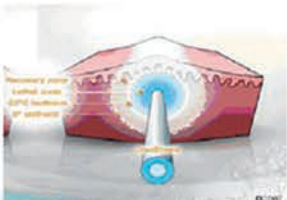
Application of Alhydran in the treatment of pathologic scars after cryoshape therapy

Personal experience

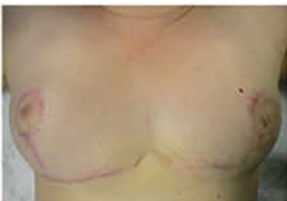BAPMEDICAL
 MEDICAL CARE FOR THE SKIN
LITERATURE SERVICE
 www.bap-medical.com



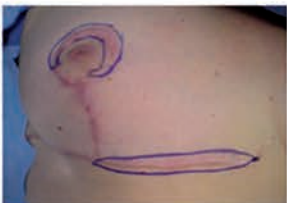Cryogun.



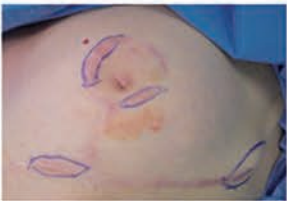How cryoshape acts on scars.
 Core of the scar at -196 °C (-320.8°F) no solution of continuity of the skin.



Clinical case: Hypertrophic scarring after bilateral reduction mammoplasty.



Close up of the scars to be treated (right breast).



Close up of the scars to be treated (left breast).

Dr. Uberto Giovannini
 Service de Chirurgie Plastique Reconstructrice et Esthétique
 Hôpital Maternité de Metz
 1/5 Place sainte croix
 57045 Metz cedex1
 Tel + 33(0)3 87345166
 e-mail: ubertogiovannini@yahoo.com

Introduction

Aloe Vera has been used as a popular herbal medicine since ancient times for many conditions. In 1851 T and H Smith of Edinburgh discovered the active principle of the plant. Aloe Vera contains 75 active constituents: vitamins, enzymes, minerals, monoacids, and acid salicyliques. After a bibliographic research on EBSCO, Medline and Google with the key words: aloe Vera, topic, surgery and wound healing, we decided to introduce the topical utilization of Aloe Vera in the treatment of scar tissue.

We decided to use Alhydran cream because of the characteristics of the pure and high concentration of the Aloe Vera, associated with high quality oils, Vitamins E and C. The cryoshape is a new technique for treating keloids and hypertrophic scars developed by Dr. Yaron Har-Shai. We present our experience with these new devices.

Materials and Methods

Technics

A specially designed cryo-needle was inserted into the long axis of the hypertrophic scars and keloids so as to maximize the volume of the hypertrophic scars and keloids to be frozen. After the hypertrophic scars and keloids were completely frozen, the cryoprobe defrosted and was withdrawn. After the treatment a dressing with Vaseline gauze was applied. The dressing was replaced after 48 hours by hydrocolloid. We started the application of Alhydran two weeks after these scars had been treated with cryoshape. The topical application was done twice a day for roughly four to six weeks.

Patients

From January 08 till July 09 we have treated 13 patients for a total of 21 scars. The age of the patients were between 17 and 62 years old

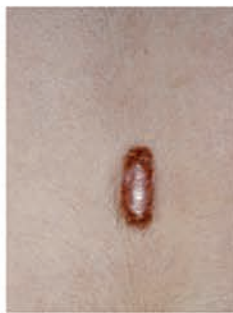5 patients presented pathologic scars after breast surgery, 2 patients after abdominal surgery, 2 patients after ear surgery, 1 patient after cleft lip surgery, 1 patient after sternotomy and one patient after burn injury.

Results

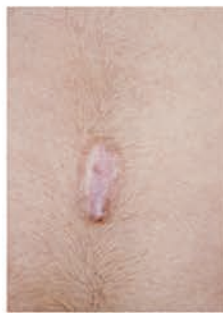None of the patients experienced an intolerance or allergy to the Alhydran. All patients experienced improvement in the scars aspect and pain and itching presented before treatment had disappeared. No adverse events were reported by any of the patients.

Conclusion

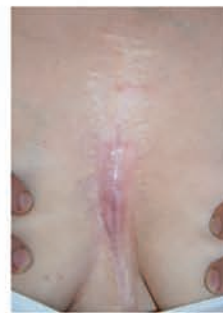Cryoshape and Alhydran showed a good synergy in the management of pathologic scars. Further, well-designed trials should be carried out to determine the effectiveness of Alhydran in improving scars outcome



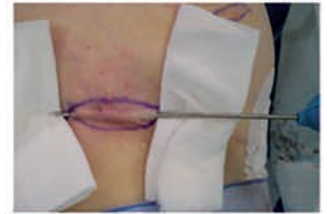
Keloid of the trunk pre operative view



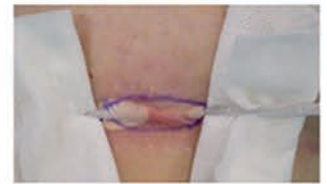Follow up at six months after one session of cryosurgery and six weeks of application of Alhydran



Follow up after six weeks of application of Alhydran



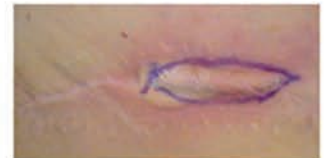Introducing the cryoshape through the scar



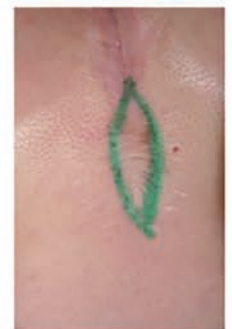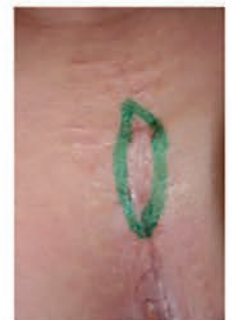Intraoperative view: you can note the freezing of the scar



Scar completely frozen.



Immediate post operative



Pathologic scars of mediastinum sequel of cardiac surgery: pre operative view before cryosurgery

Alhydran
 Aloe Vera Silver Sulfadiazine Cream for Second-Degree Burns: A Randomized Controlled Study
 Journal of Clinical Pharmacy and Therapeutics

Aloe vera: a systematic review of its clinical effectiveness
 EVIDENT
 Journal of Clinical Pharmacy and Therapeutics

Overview
 Aloe Vera for Preventing Radiation-Induced Skin Reactions: A Systematic Literature Review
 Journal of Clinical Pharmacy and Therapeutics